

# Traditional technique for removing a bent intramedullary interlocking femur nail with minimal soft tissue and bone handling

Mothilal J<sup>1</sup>, Vamsi N<sup>2</sup>, Mukund Reddy<sup>3</sup>, Srujan Sivva<sup>3</sup>

<sup>1</sup> Professor, Department of Orthopaedics, <sup>2</sup> Assistant professor, Department of Orthopaedics, <sup>3</sup> Post graduate student, Department of Orthopaedics, Prathima Institute of Medical Sciences, Karimnagar, Telangana, India.

Address for correspondence: Srujan Sivva, Postgraduate Student, Department of Orthopaedics, Prathima Institute of Medical Sciences, Karimnagar, Telangana, India.

Email: sujusrujans7a@gmail.com

## ABSTRACT

Bending of an intramedullary nail occurs due to various reasons. Bending of femoral nail due to trivial trauma in young patients is rare. Removal of a bent nail is a challenging task. In this paper, we present the management of a young patient who sustained trivial trauma and presented with a bent nail. The bent nail was corrected under image

intensifier, under spinal anaesthesia prior to scrubbing on the table. Then the nail was removed through the previous surgical incision and fixation done by exchange nailing with 1 mm more diameter intramedullary nail. Post revision surgery, there was no limb length discrepancy and the patient was able to walk with partial weight bearing with a walker.

**Key Words:** Bent intramedullary nail, Femur

Please cite this article as: Mothilal J, Vamsi N, Mukund Reddy, Srujan S. Traditional technique for removing a bent intramedullary interlocking femur nail with minimal soft tissue and bone handling. Perspectives in medical research 2014;2: 34-36

Source of Support: Nil, Conflict of interest: None Declared

## INTRODUCTION

Bent intramedullary interlocking femur nail is a rare condition with only a few cases have been documented and there is no standard treatment as such in the literature. Intramedullary nailing is the gold standard treatment for comminuted diaphyseal fracture of the femur in the present days. Bending and breakage of nail are the most important complications in this method. Bending can occur in non-union, comminuted or unstable fractures. Excessive stress may cause deformation of the implant. There are several methods reported for the removal of the bent nail. We present a case of 24 years old male, in whom the nail was bent at the fracture site after 5 months of postoperative period as a result of trauma. We did the correction using the traditional method of manipulating the nail under spinal anaesthesia and image intensifier. The bend was almost corrected and was then removed by using standard extraction technique and exchange nailing was done.

## CASE REPORT

A 24 year old male patient came to our hospital with chief complaints of pain and deformity in the right thigh, following trivial trauma. He had a history of trauma 5 months ago, for which, he was treated with open reduction and internal fixation with interlocking, intramedullary nailing and cerclage wiring. On the day before admission, he sustained a trivial fall following which he developed pain and deformity in the right thigh (figure 1). The patient was unable to stand up on his own and was brought to hospital for further management. The vitals were stable and examination revealed shortening of thigh compartment, with increased girth of thigh, with obvious deformity. There was increased femoral bend towards the lateral aspect of the thigh. The limb was adducted and patella was facing upwards with a foot in neutral position. Then radiographs of pelvis with both hips anteroposterior view and right hip with the thigh (full length) lateral view was taken which revealed non-union at the fracture site and

bending of intramedullary nail at the fracture site (figure 2,3,4). The operative planning and risks were explained to the patient. Following spinal anaesthesia, the patient was kept in a supine position and limb was flexed at the hip and knee. The sandbag is placed below the buttock, lateral to the thigh. The thigh was then abducted, two assistants stabilized the pelvis and the surgeon counteracted the abduction force from the proximal end of the lateral aspect of thigh and another assistant abducted the thigh from the medial part of the distal end. After a brief period of manipulation, the correction was checked under image intensifier and the nail was almost corrected near normal there was 5 degrees of varus under image intensifier (figure 5, 6). The patient was positioned in left lateral position, following scrubbing; right hip and thigh were draped. The fracture site was opened and the proximal cerclage wire which was at fracture site was removed then distal and proximal interlocking screws were removed. The guide wire was passed prior to the nail extraction (figure 7). Then, using the universal extractor, the nail was extracted. Now reaming was done using a flexible reamer up to 11 mm and intramedullary interlocking nail of 11 x 380 mm was placed. Proximal locking was done using zig, both dynamic and static screws were placed. The butterfly fragment was held in position and thumping was done on the knee. Then distal locking of the nail was done. After thorough washing, the wounds were closed in layers. Aseptic dressing was done. Postoperatively, radiographs of the thigh were satisfactory and there was no limb length discrepancy (figure 8,9,10). 24 hours following the surgery, the patient was made to weight bear using a walker. The patient was discharged 72 hours following surgery and was doing well at the time of discharge.

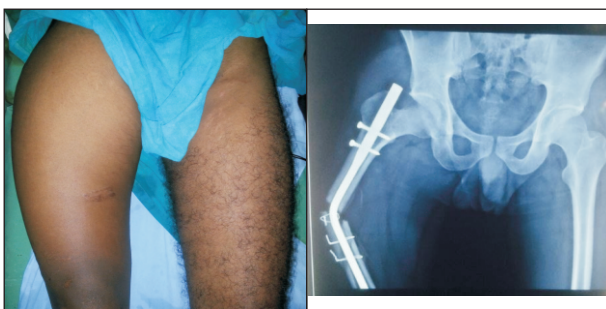
**Figure -1****Figure -2**

Figure 1: Deformity at Presentation  
 Figure 2: Preoperative radiograph showing bent intramedullary interlocking femoral nail  
 Figure 3: Bend in the nail under image intensifier before correction.

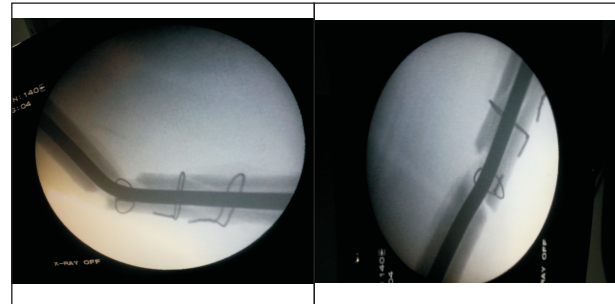
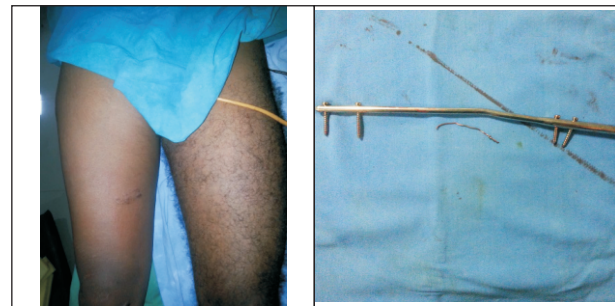
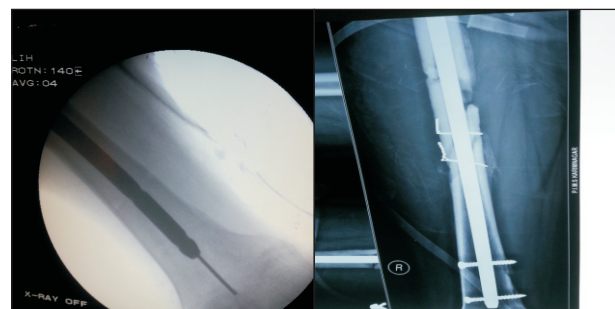
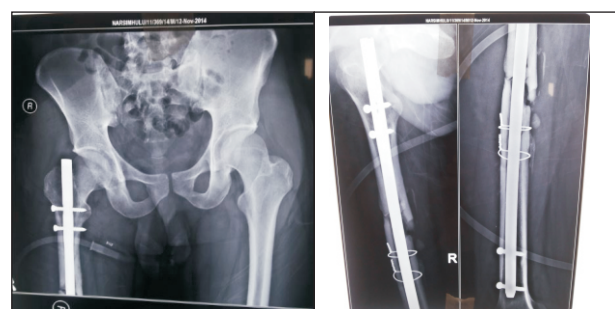
**Figure -3****Figure -4****Figure -5****Figure -6****Figure -7****Figure -8****Figure -9****Figure -10**

Figure 4: Bend in the nail under image intensifier after correction  
 Figure 5: Thigh after correction of Deformity  
 Figure 6: Deformed nail removed  
 Figure 7: Exchange nailing done through guide wire passed through old nail  
 Figure 8: postoperative radiograph right thigh-AP view  
 Figure 9: Postoperative radiograph pelvis with both hips -AP view  
 Figure 10: Postoperative radiograph right thigh lateral view

## DISCUSSION

An Intramedullary nailing fracture shaft of femur is considered a gold standard technique because of high union rates. Hundred percent union rates has been shown in some studies<sup>1-6</sup>. Intramedullary nail bending and breakage are the most important complications in this method. The bent intramedullary nail should indefinitely be removed as the nail undergoes plastic deformation and lose its strength, hence it is necessary to remove the nail and exchange nailing should be done. Removal of bent nail poses a great challenge to the surgeon. There is no standard technique described in literature for extraction of bent intramedullary femoral nail and hence there are many techniques described by various authors.<sup>6-11</sup> One such procedure for removal of bent nail is vertical osteotomy of the femur.<sup>12</sup> In this technique there is massive damage to the soft tissue and increased damage to the bone. Another technique is by drilling holes at the site of the bend and then breaking the implant,<sup>13</sup> but in this technique, there is the spilling of metal powder which increases the chance of infection. The other method is by using long dynamic compression plate and placing it using minimal invasive technique, but it poses the risk of longitudinal femur fracture.<sup>14</sup> Hence, compared to all these methods, the traditional method which is used by us is less invasive with minimal handling of bone and soft tissue. There is less damage to the already existing bone and soft tissue injury. We found this technique less cumbersome, although three more assistants are required for stabilization of pelvis and counter traction. The operative time is also similar to intramedullary nailing as correction is done before the incision is given and with less operative time and minimal soft tissue dissection, there are less chances of infection.

## CONCLUSION

The traditional method of correction of a bent intramedullary nail appears to be the best method with minimal bone and soft tissue damage.

## REFERENCES

1. W. B. LaSalle and T. Horwitz, "A method to cut and remove in situ bent intramedullary nail," *Clinical Orthopaedics and Related Research*, vol. 103, pp. 30–31, 1974.
2. P. Nicholson, J. Rice, and J. Curtin, "Management of a refracture of the femoral shaft with a bent intramedullary nail in situ," *Injury*, vol. 29, no. 5, pp. 393–394, 1998. H. Ohtsuka, K. Yokoyama, M. Tonegawa, K. Higashi, and M. Itoman, "Technique for removing a bent intramedullary femoral nail: a case report," *Journal of Orthopaedic Trauma*, vol. 15, no. 4, pp. 299–301, 2001.
3. R. H. Patterson and J. R. Ramser, "Technique for treatment of a bent Russell-Taylor femoral nail," *Journal of Orthopaedic Trauma*, vol. 5, no. 4, pp. 506–508, 1991.
4. R. K. Sen, A. Gul, S. Aggarwal, S. R. Kumar, and O. N. Nagi, "Comminuted refracture of the distal femur and condyles in patients with an intramedullary nail: a report of 5 cases," *Journal of Orthopaedic Surgery*, vol. 13, no. 3, pp. 290–295, 2005.
5. M. Wild, S. Gehrmann, P. Jungbluth et al., "Treatment strategies for intramedullary nailing of femoral shaft fractures," *Orthopedics*, vol. 33, no. 10, article 726, 2010.
6. Sonanis SV, Lampard AL, Kamat N, et al. A simple technique to remove a bent femoral intramedullary nail and broken interlocking screw. *J Trauma* 2007;63(2):435-438.
7. Apivatthakakul T, Chiewchantanakit S. Percutaneous removal of a bent intramedullary nail. *Injury* 2001;32(9):725-726.
8. Banerjee R, Posner M. Removal of a bent intramedullary nail with a posttraumatic sagittal plane deformity. *J Trauma* 2009; 66(5):1500-1503.
9. Bek D, Demiralp B, Tunay S, et al. Removal of a bent inflatable femoral nail: a case report. *Acta Orthop Traumatol Turc* 2008;42(3):211-213.
10. Bielejeski T, Garrick JG. Method of cutting in situ metallic appliances. *J Bone Joint Surg Am* 1970;52(3):585-587.
11. Biert J, Edwards MJ. Re: removal of a bent intramedullary nail with a posttraumatic sagittal plane deformity. *J Trauma* 2009;
12. Vasileios I. Sakellariou, Stamatis Kyriakopoulos, Helias Kotoulas, and Ioannis P. Sofianos. *CaseReports in Orthopedics Volume 2011 (2011)*, Article ID 614509, 4 pages.
13. Ahsan A F A Maleh and Kasper Saxtrup Nielsen. *Acfa Orthop Scand* 1998; 69 (6): 638-639.
14. Shen PC, Chen JC, Huang PJ, Lu CC, Tien YC, Cheng YM. *J Trauma*. 2011 Mar;70(3):755-8. doi: 10.1097/TA.0b013e31820009ea. A novel technique to remove bent intramedullary nail.