

Computed Tomography (CT)guided Fine Needle Aspiration Cytology of Intrathoracic Lesions

Sridhar Pulluri, Ramulu Madire*

Assistant Professor, Department of Pulmonology, Prathima Institute of Medical Sciences, Karimnagar, Telangana

*Corresponding Author:

Ramulu Madire, Assistant Professor, Department of Pulmonology, Prathima Institute of Medical Sciences, Karimnagar, Telangana

E-MAIL: dr.ramu405@gmail.com

Date of Submission: 25/10/2021

Date of Review: 12/11/2021

Date of Acceptance: 17/12/2021

ABSTRACT

B background: Diagnosis of intrathoracic masses is a difficult challenge for clinicians. The compact anatomical arrangement of the mediastinum with diverse pathologies is usually encountered. The present study was done to determine the efficiency of computed tomography (CT) guided Fine-Needle Aspiration Cytology (FNAC) in the evaluation of various thoracic mass lesions

Methods : A total of n=46 patients presenting as intrathoracic mass lesions, confirmed on contrast-enhanced CT, were included in the study. A commercially available CT (Ingenuity 128 slices, Philips) was used for biopsy. All patients were subjected to detailed clinical history and physical examination. Investigations: Complete blood count, Erythrocyte sedimentation rate, bleeding time, clotting time, Prothrombin time, Activated partial thromboplastin time, HIV and HbsAg, Chest X-ray postero Anterior view, and Lateral view done in all cases. Chest X-ray AP view and Ultrasound was done wherever needed. Plain and contrast CT was done in all cases before FNAC.

Results: The positive diagnostic yield in our study is noted in 45 of the 46 patients(97.82%); the positive yield for malignancy was 89.13% (41 of 46 patients), benign in 8.69 % (4/46), and undiagnosed in 1/46 (2.17%). Out of 46, 40(86.96%) were parenchymal lesions and 6(13.04%) were mediastinal lesions. Out of 40 parenchymal lesions, 38/40(95%) were malignant, which consisted of 55.3% Squamous cell carcinoma, 28.9% Adenocarcinoma.

Conclusion: FNAC is useful for obtaining samples for the diagnosis of focal pulmonary infections, even in immunocompromised patients, and planning appropriate chemotherapy options in lung cancer and metastatic lesions. CT-guided FNAC is an initial approach for the diagnosis of small pulmonary nodules of less than 20mm, aiding in early diagnosis and treatment interventions improving prognosis.

KEYWORDS: Computed tomography (CT), Fine-Needle Aspiration Cytology (FNAC), Intrathoracic Masses, Mediastinum

INTRODUCTION

The diagnosis of intrathoracic mass lesions by transthoracic needle aspiration was first performed over a century ago. The idea to obtain tissue fragments through a needle introduced into abnormal tissue was employed by Kun (1847), Lebert (1851), Muntrie (1886), to obtain cells and tissue fragments to diagnose cancer. [1] In 1883 Leyden used a similar technique for obtaining microorganisms causing pneumonia. [2] Almost every tissue can be sampled with this technique requiring neither anesthesia nor the expensive intervention of a surgeon. [1] In the United Kingdom in 1927, Dudgeon and Patrick proposed the needling of tumors as a means of rapid microscopic diagnosis. [1] With the recent advances in techniques such as Computed Tomography (CT), the use of Fine-Needle Aspiration Cytology (FNAC) in the diagnosis of neoplasms and infections of the lung. CT permitted precise anatomical localization of "masses" and their relationship with major vessels and plan the appropriate approach. CT also facilitated detecting small pulmonary nodules which could be overlooked on a plain radiograph. [3] The initial use of FNAC was to confirm clinical suspicion of local recurrence or metastasis or known cancer without subjecting the patients to further surgical interventions. [1] However, in recent years it is being extensively and successfully used for primary diagnosis of tumors both benign and malignant. [1] Because it is a relatively painless and inexpensive procedure, and its accuracy is reaching that of histopathology in providing an unequivocal diagnosis. Haaga and Alfridi did the first CT-guided fine needle biopsy in 1976. [4, 5] A team approach, comprising of a Pulmonologist, Radiologist, and a Cytopathologist is ideal for the success of FNAC. [6] The diagnostic rate of FNAC of lung lesions was shown to be sensitive than the bronchoscopic yield. [7] Low risk of complication allows FNAC to be performed as an office procedure in the outpatient department and radiology theatres since CT-Guided FNAC is a simple diagnostic method of relatively low cost, with negligible mortality and limited morbidity, and is more suitable for resource-poor countries. [8] With this background we in the current study tried to evaluate the diagnostic accuracy of CT guided FNAC in intrathoracic lesions in patients with thoracic lesions presenting to

our Hospital.

MATERIAL AND METHODS

This cross-sectional study was conducted in coordination with the Departments of Pulmonology, Radiology, and Pathology. Institutional Ethical permission was accorded to this study. Written consent was obtained from all the participants of the study. Lesions not amenable to ultrasonography guided biopsy or with negative bronchoscopy are included in this study.

Based on the inclusion and exclusion and sample size calculation using formula $n = Z^2 pq / E^2$ if 3% of the population is affected and the approximate population size is 500,000 then the sample size was $n=45$ we have included $n=46$ cases.

Inclusion criteria were Medical contraindications for open thoracotomy or patient refusal for thoracotomy, Inoperable presumptive carcinoma in which tissue diagnosis for preoperative irradiation or chemotherapy was required, Confirmation of localized benign disease, confirmation of a suspected malignancy/metastatic disease, unresolved pneumonia, any persistent localized lesion of the lung which could not be diagnosed adequately by conventional methods.

Exclusion criteria were Systemic bleeding tendency, Suspected vascular lesion, Previous pneumonectomy on either side, advanced or severe pulmonary hypertension, advanced pulmonary disease or severe emphysema, the inability of the patient to cooperate, suspected hydatid cyst and refusal for consent.

Sample size Estimation: Based on the inclusion and exclusion and sample size calculation using formula $n = Z^2 pq / E^2$ if 3% of the patients are affected and the approximate population size is 500,000 then the sample size was $n=45$ we have included $n=46$ cases.

A total of $n=46$ patients presenting as intrathoracic mass lesions confirmed on contrast-enhanced CT were included in the study. A commercially available CT (Ingenuity 128 slice, Philips) was used for biopsy. All patients were subjected to detailed clinical history and physical examination. Investigations: Complete blood count, Erythrocyte Sedimentation Rate, clotting time, bleeding time, prothrombin time, activated partial thromboplastin time, human immunodeficiency virus serology, Chest X-ray posterioranterior and lateral view done in all cases. Chest X-ray AP view and ultrasound was done wherever needed. Plain and contrast CT was done in all cases before FNAC. In all cases, an axial scan of the area of interest was taken to locate the lesion. The best approach was judged, and the skin puncture site was marked with a radio-opaque marker. A CT section at the level of the marker was then taken. CT guidance was used to measure the distance of the lesion from the chest wall and pleura and the distance of aerated lung noted and direction of the needle for FNAC was decided. The area of interest was then cleaned and draped as a sterile area. Subcutaneous injection of 2% xylocaine was used for local anesthesia at

the site of puncture. A 23 G Lumbar puncture needle was inserted percutaneously during suspended respiration, directing the tip of the needle towards the lesion, avoiding lung parenchymal puncture if possible and the character of the lesion was noted by noting the consistency of the lesion while the needle passed through the lesion. All specimens obtained were immediately smeared and were divided onto several slides to allow air drying and wet fixation and these slides were sent to the cytology department for staining with May-Grunwald-Giemsa (MGG) and Papanicolaou stain by a cytotechnologist. Chest radiographs were obtained 1-2 hours after FNAC, with the patient in an erect position to check for any development of pneumothorax. If pneumothorax was observed, then depending upon the size of the pneumothorax or patient's clinical status, the patients were either kept under observation for 24 hours and chest radiograph PA view was repeated or tube thoracostomy was planned.

Statistical analysis: Statistical analysis was performed with the help of SPSS 22.0 software on Windows format. Statistical analysis included the usual descriptive and univariate analysis. Student t-test was used to compare continuous variables and the test was used to compare categorical variables p-value less than 0.05 was taken as significant.

RESULT

Out of the total of $n=46$ cases studied, there were $n=34$ males (73.91%) and $n=12$ (26.09%) females details depicted in Table 1. The age range was from 14 years to 85 years and the mean age was 56.84 ± 8.5 .

Age group in years	Male	Female	Total (%)
< 20	1	0	1(2.17)
21 – 30	4	1	5(10.87)
31 – 40	2	0	2(4.35)
41 – 50	3	1	4(8.69)
51 – 60	7	3	10 (21.74)
61 – 70	8	5	13 (28.26)
71 – 80	6	2	8 (17.39)
81 – 90	3	0	3 (6.5)
Total	34	12	46 (100%)

Table 1: Distribution of cases based on age groups

Cough was the most common symptom present in 38/46 patients (82.60%), followed by breathlessness in 33/46(71.74%), fever in 24/46(52.17%), chest pain in 21/46(45.65%), weight loss in 21/46(45.65%), anorexia in 20/46(43.48%), sputum in 18/46(39.13%), hemoptysis in 9/46 (19.57%), wheeze in 6/46(13.04%), and hoarseness in 3/46(6.52%) and other symptoms in 7/46(15.22%). Table 2

Diagnosis	Malignancy	Benign	Undiagnosed
Cough	34	3	1
Sputum	18	0	0
Hemoptysis	9	0	0
Chest Pain	19	1	1
Dyspnoea	28	4	1
Wheeze	5	1	0
Fever	19	4	1
Hoarseness	3	0	0

Table 2: Distribution of symptomatology in the patients with the diagnosis

Anatomical location and the size of the lesion were noted in Figure 1. There were n=40 parenchymal and n=6 mediastinal lesions. The most common site of the lesion was the right upper lobe (n=12) in our study. The size of the lesion varied from 1.3 – 7.1cm and the average size of the lesion was 3.71cm. Most of the lesions (n=22), were between 3-5cms, n=3 lesions were very small, less than 2cms, with the smallest lesion measuring 1.3cm. N=14 lesions were between 2-3cms and n=7, were more than 5cms, with the largest lesion measuring 7.1

LLL = Left Lower Lobe; LUL = Left Upper Lobe; RLL = Right Lower Lobe; RML = Right Middle Lobe; RUL = Right Upper Lobe.

Past respiratory illness like COPD in n=15(32.61%), Bronchial Asthma in n=1(2.17%), and history of Pulmonary Tuberculosis in n=5(10.87%), were noted. Past History of Hypertension seen in n=3(6.52%), Diabetes Mellitus in n=1(2.17%). History of smoking was present in n=22(47.83%) of which n=21(4.65), were beedi smokers and n=1(2.17%) was a cigarette smoker. History of tobacco chewing was present in n=3(6.52%), history of alcohol consumption was present in n=24(52.17%) patients.

On physical examination pallor was present in n=16 (34.78%), clubbing in n=4(8.69%), cervical nodes in n=2(4.35%) dilated chest veins in n=1(2.17%) patient and increased JVP in n=1(2.17%). On systemic examination, positive respiratory signs like unilaterally decreased breath sounds, rhonchi, Crepts, etc have been depicted in table 3 and abdominal findings like hepatomegaly in n=4 (8.70%) were observed. Radiologically pleural effusion in (28.26%), collapse (32.61%), consolidation (21.74%), Mediastinal lymph node involvement in (26.09%), chest wall involvement in (19.57%), mediastinal involvement in (17.39%) and distant metastasis in (10.87%). Table 3

The positive diagnostic yield in our study is noted in 45 of the 46 patients(97.82%); the positive yield for malignancy

was 89.13% (41 of 46 patients), benign in 8.69 % (4/46), and undiagnosed in 1/46 (2.17%). Out of 46, 40(86.96%) were parenchymal lesions and 6(13.04%) were mediastinal lesions. Out of 40 parenchymal lesions, 38/40(95%) were malignant, which consisted of 55.3% Squamous cell carcinoma, 28.9% Adenocarcinoma, details are given in Table 4.

Cytological Diagnosis	Frequency (%)
Squamous Cell Carcinoma	21(45.65)
Adenocarcinoma	11(23.91)
Small Cell Carcinoma	1(2.17)
Tuberculosis	3(6.52)
Thymoma	1(2.17)
Small Cell Neuroendocrine carcinoma	1(2.17)
Seminoma	1(2.17)
Non-Hodgkin's Lymphoma	1(2.17)
Hodgkin's Lymphoma	1(2.17)
Chronic Inflammation.	1(2.17)
Nonspecific Malignancy	1(4.34)
Chondrosarcoma	1(2.17)
Inconclusive	1(2.17)

Table 4: Pathological Distribution of Lesions after Cytological Diagnosis

Fine needle aspiration cytology was performed with a 23-gauge spinal needle in all the 46 subjects under CT guidance. The pathological spectrum of lesions on cytological examination was as shown in the Out of 22 smokers 17 had Squamous cell carcinoma, 3 had adenocarcinoma, 1 had small cell carcinoma and one had malignancy (Not Otherwise Specified). The diagnosis was possible in 45(97.8%) cases and the complication rate was 4.34% with pneumothorax occurring in 2 patients which resolved spontaneously. No procedure-related mortality was observed in our study.

DISCUSSION

An early, safe, and rapid method of evaluation is needed to diagnose the majority of intrathoracic lesions to plan or institute the most appropriate treatment protocols. Clinical and imaging evaluation can only indicate the probability of malignancy or otherwise of these lesions. In the majority of the studies, FNAC confirmed its place as a diagnostic tool in the diagnosis of malignant and benign lesions and differentiation of metastatic malignancy, thereby helping the selection of specific treatment options. It is superior to a bronchoscopic evaluation in diagnosing peripheral lesions in the lung.^[9] Despite these advantages, like any other procedure, FNAC also has minor complications, which can

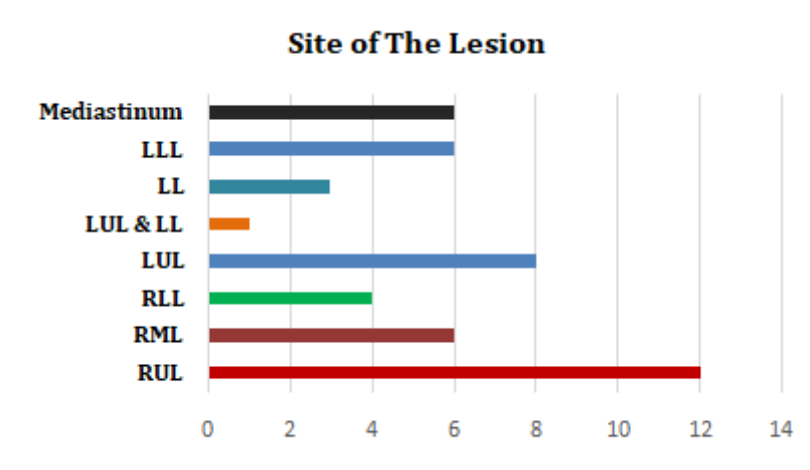


Figure 1: Anatomical location of the lesions

		Diagnosis		
		Malignancy	Benign	Undiagnosed
Crepts	Present	16	0	1
Rhonchi	Present	14	1	0
	Normal	18	4	0
Breath Sounds	Decreased Unilaterally	23	0	1
	Decreased Bilaterally	0	0	0
Pleural Effusion	Present	11	1	1
Collapse	Present	14	1	0
Consolidation	Present	9	0	1

Table 3: Respiratory Examination Findings

be managed conservatively. In our study, the emphasis was on evaluating the diagnostic accuracy of fine-needle aspiration cytology of intrathoracic lesions and its attendant complications, performed under CT guidance. Our study showed a positive cytodiagnosis in 45 of 46 patients, with a diagnostic accuracy of 97.8%. M Bakhshayesh et al., studied n=505 patients with pulmonary lesions who underwent CT-guided transthoracic FNA biopsy. The biopsy samples were adequate for diagnosis in 410 of 505 patients. 249 lesions were malignant (60.7%) and 161 (39.3%) were benign or atypical.^[10] S Mukherjee et al.,^[11] found n=90 out of a total of 94 cases were malignant. They have pointed out that if the size of lesions is greater than 3 cm the diagnostic yields are higher. In our study the size of the thoracic lesions ranged from 1.3 to 7.1 cm; 22 of the 46 patients presented with lesion sizes in the range of 3 to 5 cm. Aspiration samples were adequate for diagnosis in 45 out of 46 of our patients. The success rate of sample yield ranged between 80 to 100% and its diagnostic accuracy is described to be high between 81 and 96 percent in

various studies. JP Singh et al.^[12] in n=34 cases of thoracic masses of sizes between 1.2 to 5.6 cm, CT-guided FNAC yielded a cytodiagnosis in 29 patients' sizes between 1.2 to 5.6 cm, CT-guided FNAC yielded a cytodiagnosis in 29 patients (85.3%). A Saha et al.,^[13] found the existence of large lesions of range 5 to 10 cm. In the current study out of the 46 subjects, 40 were parenchymal lesions and six were Mediastinal lesions. A diagnosis of Squamous cell carcinoma was noted in 21 of 46 (45.65%) and Adenocarcinoma in 11 of 46 (23.91%) and Small cell carcinoma in one. In this study three metastatic lesions, one each from breast, prostate, and bone were noted. By FNAC it is usually difficult to distinguish Squamous cell carcinoma, large cell carcinoma, and Adenocarcinoma from each other, though it doesn't alter the basic treatment protocols. But FNAC can differentiate small cell carcinoma from non-small cell carcinoma which has therapeutic implications. The study followed the cytological diagnosis in conformity with the WHO classification.^[14] In the case of poorly differentiated carcinomas, the distinction between small cell versus non-

small cell carcinoma was the sole criterion.^[15] Interestingly it was noted in our study that, out of 22 smokers 17 were diagnosed as Squamous cell carcinoma, three as Adenocarcinoma, one had Small cell carcinoma, and one malignancy (Not otherwise specified). In a similar study by JP Singh et al.,^[12] the prevalence of malignancy noted was 81.8%; of the 27 cases of malignancy Squamous cell and Adenocarcinoma were six each. Six patients had benign diseases. In our study of 46 patients, 4.34% of complications were noted. Two patients developed pneumothorax, which was procedure-related, and managed conservatively. Both the patients were elderly smokers, aged 62 and 60 years. The size of the lesions was 4.7 cms (which was in proximity to the chest wall) and 1.3cms, (which was away from the chest wall) respectively. A similar observation was made in the study of 184 patients by MG Mostafa et al.,^[15] Only two (1%) patients developed pneumothorax.

Limitations of the current study: The sample size of this study was small, and the study was conducted in a well-equipped single tertiary care hospital the results may vary from one place to the other place. More data with large sample size may be required for generalization of results. However, in small rural setups, the chest radiograph is still the simplest and most effective tool in the earliest diagnosis of intrathoracic mass lesions.

CONCLUSION

FNAC is useful for obtaining samples for the diagnosis of focal pulmonary infections, even in immunocompromised patients, and planning appropriate chemotherapy options in lung cancer and metastatic lesions. CT-guided FNAC is an initial approach for the diagnosis of small pulmonary nodules of less than 20mm, aiding in early diagnosis and treatment interventions improving prognosis. Procedural complications were minor, viz., pneumothorax, which could be managed conservatively, thus making FNAC suitable for an outpatient setting.

REFERENCES

- Orell SR, Sterett GF, Whittaker D, Viehl P. Fine Needle Aspiration Cytology 4th Edition. New York: Churchill Livingstone ; 2005,.
- Padley SN, Grainger RG, Adam AD, Dixon A, Carty AK, H. Sprigg A- A textbook of Medical Imaging. Churchill Livingstone ; 2001,. p. 623–653.
- Ohno Y, Hatabu H, Takenaka D, Higashino T, Watanabe H, Ohbayashi C et al. CT-Guided Transthoracic Needle Aspiration Biopsy of Small (≤ 20 mm) Solitary Pulmonary Nodules. AJR. 2003;180:1665–69.
- Haaga JR, Alfridi RJ. Precise Biopsy Localization by Computed Tomography. Radiology March. 1976;118:603–607.
- De Wever W, Coolen J, Verschakelen JA. European Respiratory Society Monograph ; 2010,.
- Conces GRDJ, Schwenk P, Doering MDR, Glant. Thoracic needle biopsy. Improved results utilizing a team approach. Chest. 1987;91(6):813–816.
- Hwang SS, Kim HH, Park SH, Jung JI, Jang HS. The Value of CT-Guided Percutaneous Needle Aspiration in Immuno-compromised Patients with Suspected Pulmonary Infection. AJR July. 2000;175:235–238.
- Veale D, Gilmartin, Sumerling, Wadehra GJ. Prospective evaluation of fine needle aspiration in the diagnosis of lung cancer. Thorax. 1988;43:540–544.
- Rekhi B, Goard B, Kakade A, Chinoy. Scope of FNAC in the diagnosis of soft tissue tumors—a study from a tertiary cancer referral center in India. Cytojournal. 2007;4:20–20.
- Karam B, Zahirifard M, Tahbaz S, Nabatchian MO, Sadr A, M et al. CT- Guided Percutaneous Fine-Needle Aspiration Biopsy of Pulmonary Lesions. Tanaffos. 2006;5(3):37–44.
- Mukherjee S, Bandyopadhyay G, Bhattacharya A, Ghosh R, Barui G, Karmakar R. Computed tomography-guided fine needle aspiration cytology of solitary pulmonary nodules suspected to be bronchogenic carcinoma: Experience of a general hospital. J Cytol. 2010;27(1):8–9.
- Singh JP, Garg V, Setia. Computed Tomography guided transthoracic needle aspiration cytology in difficult thoracic mass lesions-Not approachable by USG. Indian Journal of Radiology and Imaging. 2004;14(4):395–400.
- Saha A, Kumar K, Manoj C, Choudhuri. Computed Tomography - Guided fine needle aspiration cytology of thoracic mass lesions: A study of 57 cases. Journal of Cytology. 2009;26(2):55–59.
- Bianocosino C, Kruger E, Vollmer L, Welker. Intraoperative fine needle aspirations - diagnosis and typing of lung cancer in small biopsies: challenges and limitations. Diagn Pathol. 2016;11:59–59.
- Golam MM. Computed tomography guided fine needle aspiration cytology in the diagnosis of thoracic lesions. J Indian Med Assoc. 2001;99:550–553.

How to cite this article: Pulluri S, Madire R. Computed Tomography (CT)guided Fine Needle Aspiration Cytology of Intrathoracic Lesions. Perspectives in Medical Research. 2022;10(1):58–62
DOI: [10.47799/pimr.1001.11](https://doi.org/10.47799/pimr.1001.11)