

A case series of bilateral optic disc oedema

Arvind R¹, Lakshmi Prasanna², Srikrishna Ingle³, Ch. JaganMohanRao⁴

¹Assistant Professor, Department of Ophthalmology ²Postgraduate student, Department of Ophthalmology, ³Associate Professor, Department of Ophthalmology, ⁴Senior resident, Department of Ophthalmology, Prathima Institute of Medical Sciences, Karimnagar, Telangana, India.

Corresponding Author: Dr. Arvind Rathod, Assistant Professor, Department of Ophthalmology, Prathima Institute of Medical Sciences, Karimnagar, Telangana, India.

Email: arvind_kmc@yahoo.co.in

ABSTRACT

Introduction : The terms papilloedema has been reserved for the passive disc swelling associated with increased intracranial pressure which is almost always bilateral although it may be asymmetrical.

Materials and Methods: 9 cases of bilateral disc oedema presented to the department of ophthalmology, Prathima Institute of Medical Sciences, Karimnagar from June 2013 to January 2014 were included in the study. Comprehensive eye examination was done. Fundus examination was done by slit lamp biomicroscopy with 90 D lens. All the patients were systemically evaluated. Radiological investigation like MRI scan of the brain was done and the diagnosis was established and treated accordingly.

Results: A total 9 cases were diagnosed with bilateral disc oedema. Of the 9 cases, 6 were females

and 3 males, age range was between 19-55 years. Most of the patients had good visual acuity at presentation. The most common complaint was headache associated with blurring of vision. Of the 9 cases, 3 patients diagnosed as idiopathic intracranial hypertension, 1 each was diagnosed as malignant hypertension, pituitary adenoma and craniopharyngioma . Two cases were diagnosed as cavernous venous sinus thrombosis and one was diagnosed as optic neuritis.

Conclusion: It is important to evaluate fundus in each and every case presenting with headache and transient visual obscuration to rule out any underlying cause of raised intracranial pressure.

Key words: Optic disc oedema, Idiopathic intracranial hypertension, Cavernous venous sinus thrombosis

Please cite this article as: Arvind R, Prasanna L, Ingle S, Ch. JaganMohanRao. A case series of bilateral optic disc oedema. Perspectives in medical research 2014;2:37-40

Source of Support: Nil, Conflict of interest: None Declared

INTRODUCTION

Compression of the optic nerve is caused by a variety of reasons which may lead to dysfunction or, a partial arrest of axoplasmic transport and may manifest as optic disc edema.¹ The term papilledema is commonly referred to a condition of the optic nerve due to raised intracranial pressure. The term *optic disc edema* can be used instead of papilledema, in case if the disc edema is not because of increased intracranial pressure. Pathophysiology of optic disc swelling is due to blockage of axoplasmic transport, which may be because of mechanical and vascular causes.^{1, 2, 3, 4} Idiopathic intracranial hypertension (IIH) is a condition in which neuroimaging is negative for mass lesions and obstruction of the ventricular system. A lumbar puncture reveals a

high opening pressure with normal fluid composition. In young adults, papilledema is more likely due to IIH rather than real tumor. Use of medications like tetracycline, minocycline, lithium, isotretinoin, nalidixic acid, corticosteroids and oral contraceptives may lead to IIH. Other conditions like chronic respiratory insufficiency, renal syndrome, iron deficiency anemia, and obstructive sleep apnea also have been associated with IIH.^{5,6}

The treatment of papilledema associated with visual loss must focus on evaluation of the cause, and attempts must be made to address the pathophysiology. Management of IIH mainly includes the administration of diuretics, especially carbonic anhydrase inhibitors and weight reduction. Serial lumbar punctures may also be helpful. Optic nerve

sheath decompression or a ventriculo- and lumbo-peritoneal shunts can be done in case if the patient is not responding to the medical management. Tumours benign or malignant should undergo surgical removal.^{7,8,9}

MATERIALS AND METHODS

A study of 9 cases of bilateral disc oedema presented to the department of ophthalmology, Prathima Institute of Medical Sciences, Karimanagar from June 2013 to January 2014 were included in the study. Detailed history of patients' complaints was noted. All patients had a comprehensive eye examination including visual acuity at presentation. All patients underwent complete fundus examination by using slit lamp biomicroscopy using 90 D lens and also indirect ophthalmoscopy.

Fundus photographs were taken of all the patients. Patients diagnosed with Bilateral disc oedema were systemically evaluated. Investigations like complete blood picture, random blood sugar and other necessary haematological investigations were done. Neuro imaging like Magnetic resonance imaging of brain with or without contrast was done depending upon the condition required.

Patients were diagnosed and treated accordingly. Patients with intracranial space occupying lesions were referred to the department of neurosurgery for further management.

Patients with bilateral disc oedema with normal neuroimaging were suspected for idiopathic intracranial hypertension. Cerebrospinal fluid analysis was done and opening pressure of cerebrospinal fluid is noted. Young Patients with normal neuroimaging and raised cerebrospinal fluid pressure were diagnosed as IIH and treated with Carbonic Anhydrase inhibitors and referred to the department of neurology for further management.

Idiopathic intracranial hypertension patients were followed up for any visual field defects and visual field tests like automated perimetry was performed.

RESULTS

In this case series, 9 patients were diagnosed with bilateral disc oedema. Of the 9 patients, 6 were females and 3 were males. The age range was 19- 55 years. Eight patients had visual acuity ranging from 6/9 to 6/24 by Snellens chart at presentation. One patient had visual acuity of counting fingers less than 3 meters at presentation. Chief complaint of the patients was headache, sometimes associated with

blurring of vision and 2 patients presented headache as their only complaint. Four patients had headache associated with blurring of vision and 3 patients complained of diplopia and headache. One patient presented with Abducens nerve palsy with the complaint of double vision.

Three patients were diagnosed with IIH. Common age of presentation with idiopathic intracranial hypertension ranged from 19- 35 years. All the three patients were females. Magnetic resonance imaging of these patients was normal. Lumbar puncture for cerebrospinal fluid analysis showed increased opening pressure. All patients were followed regularly for any visual field defect by automated perimetry. Two cases were diagnosed with cavernous sinus thrombosis. One each patient was diagnosed with malignant hypertension, Craniopharyngioma, pituitary adenoma and bilateral optic neuritis.

CASE REPORTS

Case 1

A 20 year old female presented with headache and blurring of vision, fundus showed bilateral disc oedema. MRI Brain was normal, lumbar puncture done for CSF analysis showed increased opening pressure and diagnosed as idiopathic intracranial hypertension. The condition was treated with acetazolamide 250 mg four times a day. Three months after treatment, optic disc oedema resolved. Patient followed periodically with visual field testing by Perimetry.

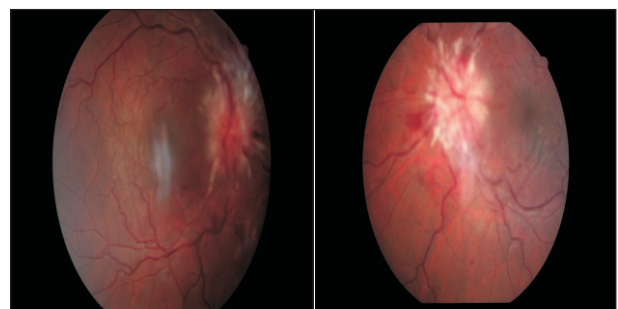


Figure -1

Figure -2

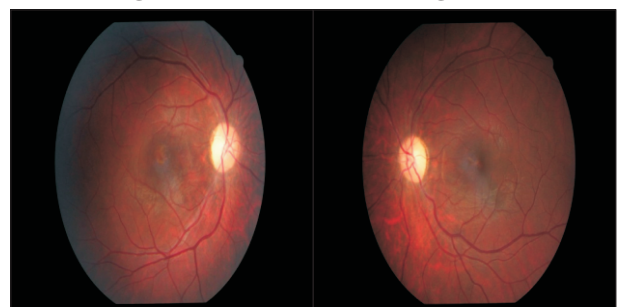


Figure -3

Figure -4

Figure 1: Right eye, optic disc oedema

Figure 2: Left eye, optic disc oedema

Figure 3: Resolved right eye optic disc oedema, after 3 months

Figure 4: Resolved left eye optic disc oedema, after 3 months

Case 2

A 35 year old female patient presented with headache since 7 days, visual acuity was 6/6 by snellens chart in both eyes. Fundus showed bilateral disc oedema. Blood pressure was 220/ 140 mmHg. The patient was diagnosed as malignant hypertension and referred to internal medicine department for further management.

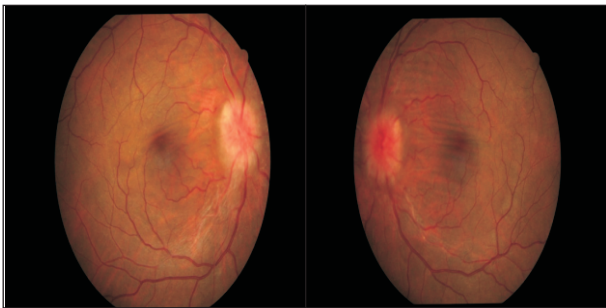


Figure -5

Figure -6

Figure 5: Right eye, optic disc edema

Figure 6: Left eye, optic disc edema

Case 3

A 40 year old male presented with double vision since 7 days. Best corrected visual acuity was 6/18 in both eyes. Left eye showed esodeviation and reduction in abduction, levelevation and levodepression. Fundus showed bilateral optic disc oedema. MRI Brain revealed pituitary adenoma. The patient was diagnosed as both eyes papilloedema with abducens nerve palsy due to pituitary adenoma and referred to the neurosurgery department for further management.

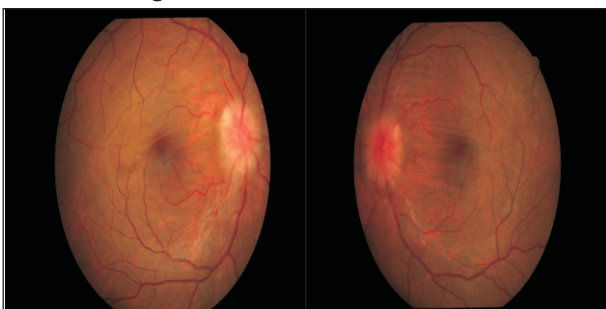


Figure -7

Figure -8

Figure 7: Right eye, optic disc edema

Figure 8: Left eye, optic disc edema

DISCUSSION

Bilateral disc edema is caused by varied causes. Most common cause being raised intracranial pressure. Patients presented with bilateral disc oedema should be suspected for raised intracranial pressure unless proved otherwise.

In our case series 7 patients out of 9, had bilateral disc oedema due to raised intracranial pressure. The findings of our study are consistent with the findings of the study done by Kei et al who showed that increased intracranial pressure accounted for approximately 60% of cases in the studied population.¹⁰

Common diseases that causes raised intracranial pressure are intracranial space occupying lesions, in our case series two patients presented with an intracranial space occupying lesion, one was diagnosed as craniopharyngioma and other with pituitary adenoma. Both patients presented with headache associated with visual obscurations. Another common disease that leads to raised intracranial pressure is idiopathic intracranial hypertension, although CT and MRI of brain appear normal. It is commonly seen in young, obese female in their reproductive age group, also seen in patients using oral contraceptives and other systemic medications.

In our case series, age of presentation of patients with idiopathic intracranial hypertension ranged from 19 to 35 years, it was comparable to a study by Wall et al on idiopathic intracranial hypertension with an age range of 11 to 58 years.¹¹

A common symptom of bilateral disc oedema at presentation was headache with or without transient visual obscuration. Study by Wall et al showed headache was presenting complaint in 92 % and visual obscuration in 72 % of cases was comparable to our case series, which showed headache was presenting symptom in more than 90 % of cases.¹¹ In a recent Dutch European study, common symptom as headache accounting for 95% , was comparable to our study.¹²

Another disease that typically shows elevated intracranial pressure despite normal CT and MRI is cavernous sinus venous thrombosis. Magnetic resonance venography can be done to confirm the diagnosis of cavernous sinus venous thrombosis, it shows venous filling defects because it enables clear visualization of major intracranial veins and cranial sinuses.

CONCLUSION

It is important to evaluate all the patients presenting with headache and transient visual obscuration for

complete eye examination including visual acuity and fundus examination to rule out any optic disc oedema. If Disc oedema is seen on fundus examination, patients should be investigated systemically and neuroimaging like CT or MRI should be done to establish the cause of disc oedema and treated accordingly. Visual loss is common in patients with Idiopathic Intracranial Hypertension and is often reversible. Patients should be followed regularly for visual field defects by perimetry and contrast sensitivity along with careful examination of the optic disc.

REFERENCES

1. Hayreh MS, Hayreh SS. Optic disc edema in raised intracranial pressure. I. Evolution and resolution. *Arch Ophthalmol* 1977; 95:1237-1244.
2. Hayreh SS. Optic disc edema in raised intracranial pressure. V. Pathogenesis. *Arch Ophthalmol* 1977;95:1553-1565.
3. Minckler DS, Bunt AH. Axoplasmic transport in ocular hypotony and papilledema in the monkey. *Arch Ophthalmol* 1977;95:1430-1436.
4. Tso MO, Hayreh SS. Optic disc edema in raised intracranial pressure. III. A pathologic study of experimental papilledema. *Arch Ophthalmol* 1977;95:1448-1457.
5. Marcus DM, Lynn J, Miller JJ, Chaudhary O, Thomas D, Chaudhary B. Sleep disorders: a risk factor for pseudotumor cerebri. *J Neuroophthalmol* 2001; 21:121-123.
6. Lee AG, Golnik K, Kardon R, Wall M, Eggenberger E, Yedavally S. Sleep apnea and intracranial hypertension in men. *Ophthalmology*. 2002 Mar;109(3):482-5.
7. Brouman ND, Spoor TC, Ramocki JM. Optic nerve decompression for pseudotumor cerebri. *Arch Ophthalmol* 1988; 106:1378-1383.
8. Corbett JJ, Nerad JA, Tse DT, Anderson RL. Results of optic nerve sheath fenestration for pseudotumor cerebri: the lateral orbitotomy approach. *Arch Ophthalmol* 1988; 106:1391-1397.
9. Tytla ME, Buncic JR. Recovery of spatial vision following shunting for hydrocephalus. *Arch Ophthalmol* 1990; 108:701-704.
10. Kei Lijima, Shimiju K. A study of the causes of bilateral disc oedema in Japanese population. *Clin Ophthalmol* 2014; 8: 1269–1274.
11. Wall M. Idiopathic Intracranial Hypertension. *Neurol Clin*. Aug 2010; 28(3): 593–617.
12. de Bruin S, de Haan R, Stam J. Clinical features and prognostic factors of cerebral venous sinus thrombosis in a prospective series of 59 patients. *J Neurol Neurosurg Psychiat* 2001; 70:105–8.